

Short communication

COVID-19 mRNA vaccine BNT162b2 induces autoantibodies against type I interferons in a healthy woman

Wangbin Ning^{a,b}, Wanli Xu^c, Xiaomei Cong^c, Hongkuan Fan^{d,e}, Gary Gilkeson^{f,g}, Xueling Wu^h, Heather Hughes^{g,i}, Wei Jiang^{a,g,i,*}

^a Department of Microbiology and Immunology, Medical University of South Carolina, Charleston, SC, USA

^b Department of Rheumatology and Immunology, Xiangya Hospital, Central South University, Changsha, Hunan, China

^c University of Connecticut School of Nursing, Storrs, Connecticut, 06269, USA

^d Department of Pathology and Laboratory Medicine, Medical University of South Carolina, 173 Ashley Ave., MSC 908, CRI Room 610, Charleston, SC, 29425, USA

^e Department of Regenerative Medicine and Cell Biology, Medical University of South Carolina, Charleston, SC, 29425, USA

^f Division of Rheumatology and Immunology, Department of Medicine, Medical University of South Carolina, Charleston, SC, USA

^g Ralph H. Johnson VA Medical Center, Charleston, SC, USA

^h Aaron Diamond AIDS Research Center, Columbia University Vagelos College of Physicians and Surgeons, New York, NY 10032, USA

ⁱ Division of Infectious Diseases, Department of Medicine, Medical University of South Carolina, Charleston, SC, 29425, USA

ARTICLE INFO

Keywords:

COVID-19

COVID-19 mRNA vaccine BNT162b2

Autoantibodies against type I interferons

ABSTRACT

Coronavirus disease (COVID-19) caused by SARS-CoV-2 virus is associated with a wide range of clinical manifestations, including autoimmune features and autoantibody production in a small subset of patients. Pre-existing neutralizing autoantibodies against type I interferons (IFNs) are associated with COVID-19 disease severity. In this case report, plasma levels of IgG against type I interferons (IFNs) were increased specifically among the 103 autoantibodies tested following the second shot of COVID-19 vaccine BNT162b2 compared to pre-vaccination and further increased following the third shot of BNT162b2 in a healthy woman. Unlike COVID-19 mediated autoimmune responses, vaccination in this healthy woman did not induce autoantibodies against autoantigens associated with autoimmune diseases. Importantly, IFN- α -2a-induced STAT1 responses in human PBMCs *in vitro* were suppressed by adding plasma samples from the study subject post- but not pre-vaccination. After the second dose of vaccine, the study subject exhibited severe dermatitis for about six months and responded to treatments with Betamethasone Dipropionate Ointment and antihistamines for about one month. Immune responses to type I IFN can be double-edged swords in enhancing vaccine efficacy and immune responses to infectious diseases, as well as accelerating chronic disease pathogenesis (e.g., chronic viral infections and autoimmune diseases). This case highlights the BNT162b2-induced neutralizing anti-type I IFN autoantibody production, which may affect immune functions in a small subset of general population and patients with some chronic diseases.

Author statement

The Institutional Review Board at the University of Connecticut approved this study for human, and the participant gave informed consent.

1. Introduction

Coronavirus disease 2019 (COVID-19) is an infectious disease caused by Severe Acute Respiratory Coronavirus 2 (SARS-CoV-2). Evidence suggests SARS-CoV-2 infection can induce autoantibody production by

disturbing self-tolerance and triggering autoimmune responses through cross-reactivity with host cells [1,2]. Autoantibodies against type I interferons (IFN-I) have been identified as a risk factor for patients with life-threatening COVID-19 [3]. Vaccines are critical tools to help reduce the SARS-CoV-2 infection and severity of COVID-19 [4]. Common side effects of COVID-19 mRNA vaccine include mild-to-moderate pain at the injection site, fatigue, and headache [5]. The cutaneous adverse events occurred in almost 30% of individuals following COVID-19 mRNA vaccine [6]. The most common cutaneous complications were focal injection site reaction, exanthematous rash, and urticaria [5]. The adverse effect of triggering autoimmune features following COVID-19 mRNA

* Corresponding author. 173 Ashley Ave. BSB214C, Charleston, SC, 29425, USA.

E-mail addresses: jianw@musc.edu, wei.jiang1@va.gov (W. Jiang).

<https://doi.org/10.1016/j.jaut.2022.102896>

Received 24 June 2022; Received in revised form 10 August 2022; Accepted 11 August 2022

Available online 18 August 2022

0896-8411/Published by Elsevier Ltd.

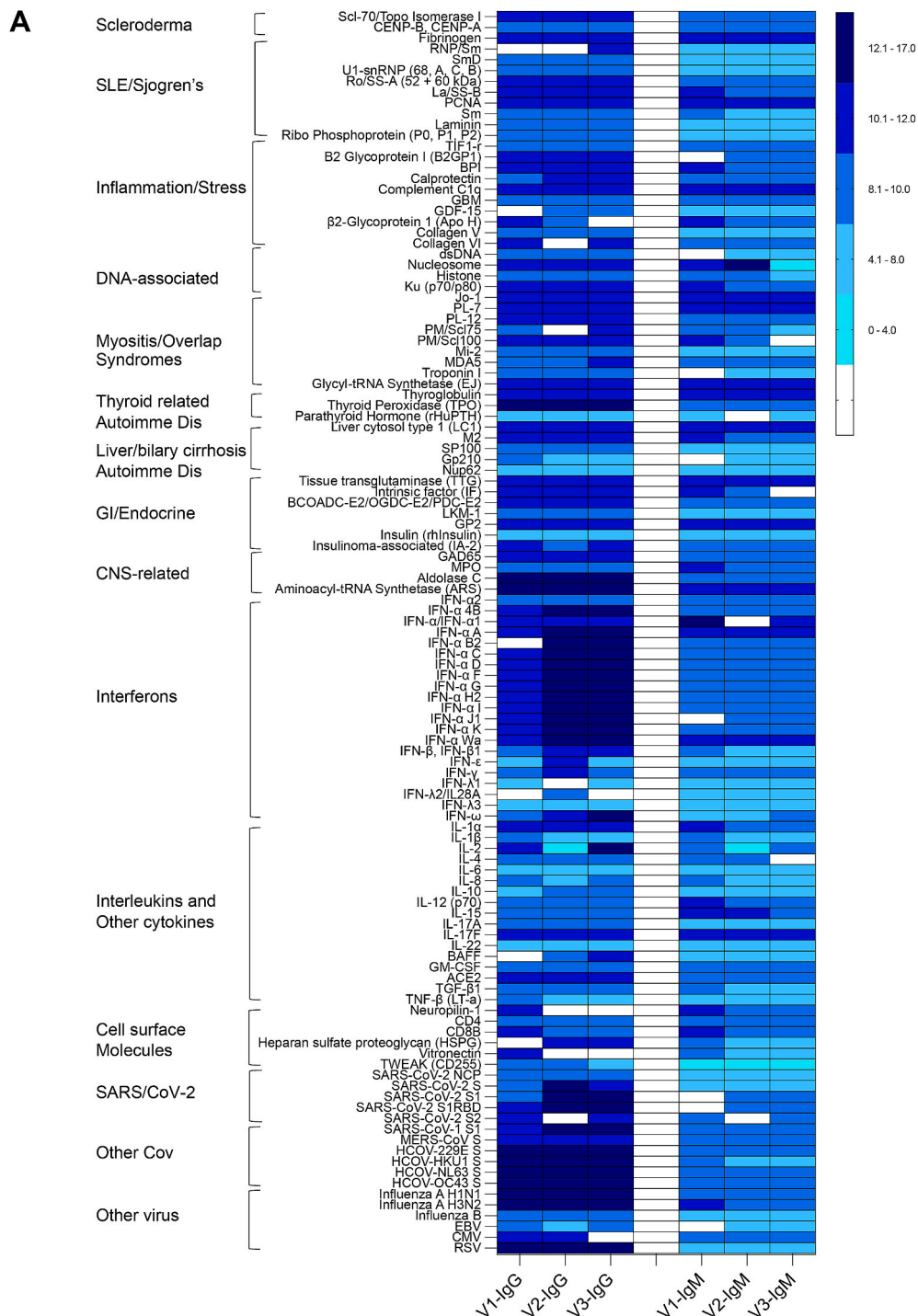


Fig. 1. Increased plasma IgGs against type I IFN following COVID19 mRNA vaccine BNT162b2. (A) A heat map figure shows plasma levels of IgM and IgG responses against 115 antigens pre- and post-COVID19 mRNA vaccine BNT162b2. According to the normalized signal intensity (NFI) value, $\log_2(\text{NFI}+1)$ is calculated. Plasma levels of IgG against SARS-CoV-2 S proteins (B) and against type I, II, and III IFN antigens (C) among the three study visits. (D) The post-vaccination plasma suppressed IFN- α -2a-induced STAT1 responses *in vitro*. Plasma samples were added to the media of PBMC culture from four healthy individuals in the presence of IFN- α -2a (100 ng/mL) or medium. The STAT1 protein expression was evaluated in medium and 10% plasma from pre- and post-vaccination (visit 3). Non-parametric MannWhitney U tests. (E) Skin rashes at the active and recovery phases as well as pathologic diagnosis.

vaccines has been reported by case reports, but the symptoms often resolved quickly and the clinical course was typically benign [7–10]; in addition, whether the noted autoimmune syndromes were induced by vaccination versus happened concurrently is not always clear. Other studies have not noted an association of vaccination with flares in autoimmune reactions following COVID-19 mRNA vaccination [11].

Nonetheless, immune-mediated disease flare and onset are rare following COVID-19 mRNA vaccination [12]. Here, we report a case of IgG autoantibody production against type I IFN in a 50-year-old healthy woman following the second and third shots of COVID19 mRNA vaccine BNT162b2; she also presented dermatitis reflected by the left inferior lateral shin excoriated indurated hyperkeratotic plaques for about six

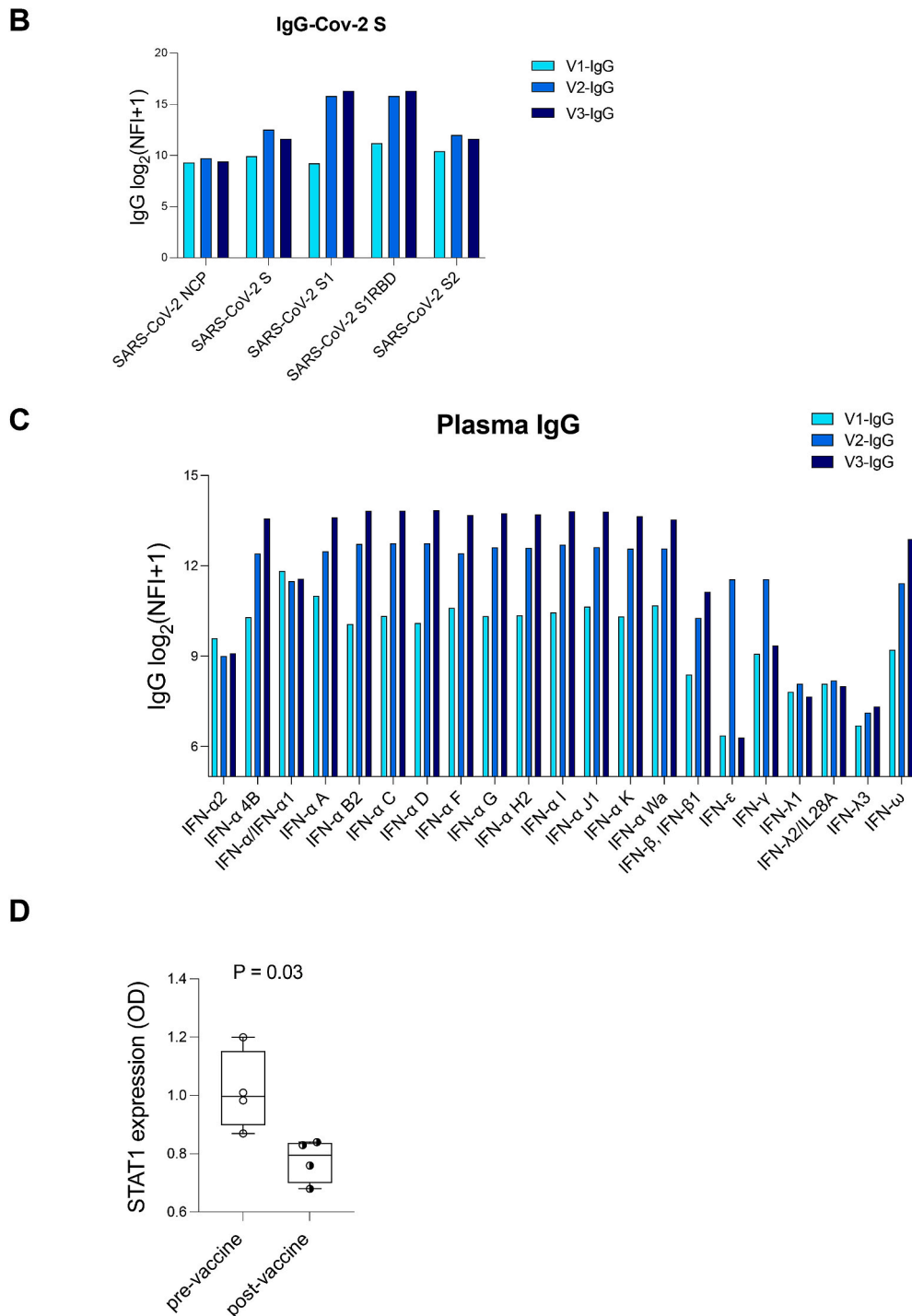


Fig. 1. (continued).

months following the second dose of vaccine. This case highlights the fact that COVID19 mRNA vaccine BNT162b2 can induce specific autoantibodies, which may have implications for clinical patient care.

2. Case presentation

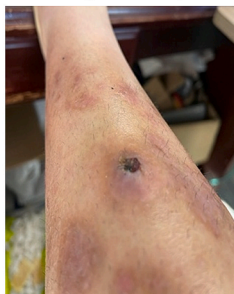A 50-year-old female has no autoimmune disease history or family history or any other disease and does not take any medicine during 2020–2021. She received three doses of COVID-19 mRNA vaccine BNT162b2, the first shot on January 6, 2021, the second shot on January 29, 2021, and the third shot on September 17, 2021. Her plasma samples

were collected at three visits, pre-vaccination (visit 1), 6-month after the second shot of vaccination (visit 2), and 3-month after the third shot of vaccination (visit 3). This study was approved by the institutional review board from the University of Connecticut School.

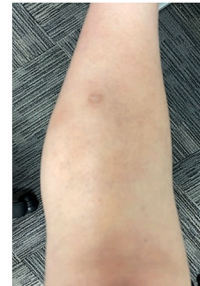
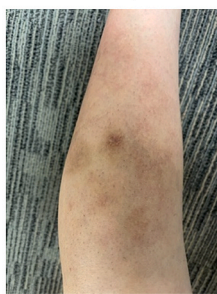
Plasma antibody levels against a number of viral antigens including SARS-CoV-2 and autoantigens were evaluated by the OmicsArray™ autoantigen protein microarray chip (GeneCopoeia, Rockville, MD, USA). The vaccine-related antibody specificity against SARS-CoV-2 S1 protein was confirmed by increased plasma levels of IgGs against SARS-CoV-2 S, S1, and SARS-Cov-2 S1RBD post-vaccination compared to baseline (Fig. 1A–B).

E**Skin rash, left inferior lateral shin**

Skin rashes at the active phase
September, 2021



Skin rashes at the recovery phase
December, 2021 July, 2022

**FINAL DIAGNOSIS:**

Skin, Left Inferior Lateral Shin, Punch Biopsy: **Lichen simplex chronicus (L28.0)**.

CLINICAL IMPRESSION:

Skin, Left Inferior Lateral Shin, Punch Biopsy. Excoriated indurated hyperkeratotic plaques. DDX: Dermatitis vs. Eczema vs. Psoriasis.

GROSS DESCRIPTION:

Received a punch biopsy measuring 4 x 4 x 3 mm. The specimen is bisected and submitted in one cassette.

MICROSCOPIC DESCRIPTION:

The epidermis exhibits irregular psoriasiform hyperplasia with hypergranulosis and marked compact hyperkeratosis. The papillary dermis is fibrotic and thickened with collagen in vertical streaks.

Skin rash, right knee

July, 2022

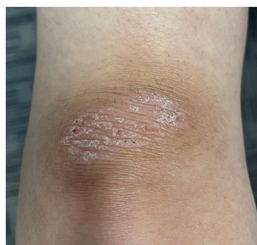

Fig. 1. (continued).

Similar plasma levels of IgG and IgM autoantibodies were observed in the three visits, including autoantigens associated with autoimmune diseases, inflammation/stress, and cell-associated molecules (Fig. 1A). Unexpectedly, we found that plasma levels of IgG autoantibodies against type I interferons (IFNs), including IFN- α 4B, IFN- α A, IFN- α B2, IFN- α C, IFN- α D, IFN- α F, IFN- α G, IFN- α H2, IFN- α I, IFN- α J1, IFN- α K, IFN- α Wa, IFN- β , IFN- β 1, IFN- ω , were increased post-compared to pre-vaccination (Fig. 1C). IgG of IFN- ϵ , IFN- γ increased in visit 2 compared to visit 1 but decreased in visit 3. IgG against IFN-type III, IFN- λ and levels of IgM did not differ in the three visits. Furthermore, post-vaccination plasma samples suppressed type I IFN- α -2a induced STAT1 protein expression in PBMCs from 4 healthy individuals (ELISA, RAB0441, Sigma, St. Louis, MO) (Fig. 1D).

The study subject started to have itchy rashes on the left lower limb around February 2021 and developed into severe dermatitis, which was not effective using a cream with glucocorticoid formulation. Until October 4, 2021, she went to see a dermatologist, got a puncture biopsy of the rash, and was diagnosed with dermatitis. Her rashes were

recovered using an antihistamine (Allegra, 1 tablet per day) and beta-methasone dipropionate ointment USP (0.05%, once per day) for about 3 weeks (Fig. 1E).

COVID-19 infection is associated with autoimmune features and autoantibody production in a small subset of patients with autoimmune diseases [1,2]. Pre-existing neutralizing autoantibodies against type I IFNs are associated with COVID-19 disease severity [3]. In this case report, a healthy woman produced IgG autoantibodies against type I IFNs with neutralizing activity following the second dose, and were further accentuated following the third dose of vaccine BNT162b2. Notably, BNT162b2 did not induce autoantibodies related to autoimmune diseases or other cellular autoantigens, which differs from the autoantibodies induced by COVID-19 infection [1,2].

There are several potential mechanisms accounting for BNT162b2-mediated anti-type I IFN autoantibodies: 1) antigen mimicry between BNT162b2-mediated S protein and human type I IFN. 2) The COVID-19 mRNA may have the innate immune activity through endosomal and cytoplasmic nucleic acid receptors including toll-like receptor (TLR)7 or

TLR9, or components of the inflammasome. 3) Non-TLR adjuvant effects. For example, the lipid nanoparticle is used in the BNT162b2 vaccine and has the adjuvant effect by inducing robust T follicular helper cell and humoral responses [13].

It has become increasingly apparent that innate immunity is critical for the induction of virus-specific adaptive immune responses [14]. Thus, the type I IFN innate-mediated immune responses can be double-edged swords in enhancing vaccine efficacy and immune responses to acute infectious diseases, as well as accelerating chronic disease pathogenesis (e.g., chronic viral infections, cancer, and autoimmune diseases) [15,16]. This case highlights BNT162b2-induced neutralizing anti-type I IFN autoantibodies, which may affect vaccine efficacy or chronic disease pathogenesis in some patients and deserves further investigations.

The authors declare no competing financial or non-financial interests.

Data availability

Data will be made available on request.

Acknowledgments

This work was supported by grants from the National Institutes of Health: R01GM130653 (Fan), R01NR016928 (Cong), R01AI128864 (Jiang), and DA057164 (Jiang), NIH/NCATS grant UL1TR001450, as well as by Merit Review Award Number CX002422 (Jiang) from the United States (U.S.) Department of Veterans Affairs Office of Research and Development (BLR&D) Service, the UConn InCHIP Faculty Seed Grant (Xu), and Oncology Nursing Foundation Research Grant (Xu).

References

- [1] C. Galeotti, J. Bayry, Autoimmune and inflammatory diseases following COVID-19, *Nat. Rev. Rheumatol.* 16 (8) (2020) 413–414.
- [2] Y. Chen, Z. Xu, P. Wang, X.M. Li, Z.W. Shuai, D.Q. Ye, H.F. Pan, New-onset Autoimmune Phenomena Post-COVID-19 Vaccination, 2021. *Immunology*.
- [3] Bastard P, Rosen LB, Zhang Q, Michailidis E, Hoffmann HH, Zhang Y, Dorgham K, Philippot Q, Rosain J, Beziat V et al.: Autoantibodies against type I IFNs in patients with life-threatening COVID-19. *Science* 2020, 370(6515).
- [4] L.R. Baden, H.M. El Sahly, B. Essink, K. Kotloff, S. Frey, R. Novak, D. Diemert, S. A. Spector, N. Rouphael, C.B. Creech, et al., Efficacy and safety of the mRNA-1273 SARS-CoV-2 vaccine, *N. Engl. J. Med.* 384 (5) (2021) 403–416.
- [5] F.P. Polack, S.J. Thomas, N. Kitchin, J. Absalon, A. Gurtman, S. Lockhart, J. L. Perez, G. Perez Marc, E.D. Moreira, C. Zerbini, et al., Safety and efficacy of the BNT162b2 mRNA Covid-19 vaccine, *N. Engl. J. Med.* 383 (27) (2020) 2603–2615.
- [6] M.R. Pourani, M. Shahidi Dadras, M. Salari, R. Diab, N. Namazi, F. Abdollahimajid, Cutaneous adverse events related to COVID-19 vaccines: a cross-sectional questionnaire-based study of 867 patients, *Dermatol. Ther.* 35 (2) (2022), e15223.
- [7] M. Ghielmetti, H.D. Schaufelberger, G. Mieli-Vergani, A. Cerny, E. Dayer, D. Vergani, B. Terziroli Beretta-Piccoli, Acute autoimmune-like hepatitis with atypical anti-mitochondrial antibody after mRNA COVID-19 vaccination: a novel clinical entity? *J. Autoimmun.* 123 (2021), 102706.
- [8] M. Obeid, C. Fenwick, G. Pantaleo, Reactivation of IgA vasculitis after COVID-19 vaccination, *Lancet Rheumatol* 3 (9) (2021) e617.
- [9] K.A. Terracina, F.K. Tan, Flare of rheumatoid arthritis after COVID-19 vaccination, *Lancet Rheumatol* 3 (7) (2021) e469–e470.
- [10] X. Li, X. Tong, W.W.Y. Yeung, P. Kuan, S.H.H. Yum, C.S.L. Chui, F.T.T. Lai, E.Y. F. Wan, C.K.H. Wong, E.W.Y. Chan, et al., Two-dose COVID-19 vaccination and possible arthritis flare among patients with rheumatoid arthritis in Hong Kong, *Ann. Rheum. Dis.* 81 (4) (2022) 564–568.
- [11] U.M. Geisen, D.K. Berner, F. Tran, M. Sumbul, L. Vullriede, M. Ciripoi, H.M. Reid, A. Schaffarzyk, A.C. Longardt, J. Franzenburg, et al., Immunogenicity and safety of anti-SARS-CoV-2 mRNA vaccines in patients with chronic inflammatory conditions and immunosuppressive therapy in a monocentric cohort, *Ann. Rheum. Dis.* 80 (10) (2021) 1306–1311.
- [12] A. Watad, G. De Marco, H. Mahajna, A. Druyan, M. Eltit, N. Hijazi, A. Haddad, M. Elias, D. Zisman, M.E. Naffaa, et al., Immune-mediated disease flares or new-onset disease in 27 subjects following mRNA/DNA SARS-CoV-2 vaccination, *Vaccines* 9 (5) (2021).
- [13] M.G. Alameh, I. Tombacz, E. Bettini, K. Lederer, C. Sittplangkoon, J.R. Wilmore, B. T. Gaudette, O.Y. Soliman, M. Pine, P. Hicks, et al., Lipid nanoparticles enhance the efficacy of mRNA and protein subunit vaccines by inducing robust T follicular helper cell and humoral responses, *Immunity* 54 (12) (2021) 2877–2892 e2877.
- [14] J. McGill, J.W. Heusel, K.L. Legge, Innate immune control and regulation of influenza virus infections, *J. Leukoc. Biol.* 86 (4) (2009) 803–812.
- [15] K.B. Elkon, A. Wiedeman, Type I IFN system in the development and manifestations of SLE, *Curr. Opin. Rheumatol.* 24 (5) (2012) 499–505.
- [16] L.M. Snell, T.L. McGaha, D.G. Brooks, Type I interferon in chronic virus infection and cancer, *Trends Immunol.* 38 (8) (2017) 542–557.